

CASE REPORT

Paroxetine Induced QT Prolongation in a Patient Undergoing Lumbar Spinal Fusion Surgery

Sharath Krishnaswami* and Dheeraj Masapu

¹Department of Neuroanaesthesia and Neurocritical Care, Aster Whitefield Hospital, Bangalore, India

*Corresponding author: Krishnaswami S, Department of Neuroanaesthesia and Neurocritical Care, Aster Whitefield Hospital, Bangalore, India | Email: sharathkrishnaswami[AT]gmail.com

Received: November 29, 2025; Accepted: January 09, 2026; Published: January 19, 2026

DOI: <https://doi.org/10.70620/CRROA/v7i1/153>



[All articles published by Gnoscience are Open Access under the Creative Commons Attribution License BY-NC-SA](#)

Abstract

Paroxetine is a selective serotonin reuptake inhibitor (SSRI). It is used to treat several diseases, including major depressive disorder, obsessive-compulsive disorder, post-traumatic stress disorder, generalized anxiety disorder, and premenstrual dysphoric disorder. Anaesthesia or surgery may exacerbate the cardiac effects of the drug. Its interaction with anaesthetic drugs may also have an effect on the heart rhythm. In this case report, the mechanism of such an arrhythmia is elucidated upon. We report a case of acquired QT prolongation in a patient receiving paroxetine who underwent lumbar spinal fusion surgery under general anaesthesia. The potential mechanisms, perioperative implications, and management strategies for acquired QT prolongation are discussed.

Keywords: Paroxetine; SSRI; Depressive disorder; Anxiety; QT prolongation.

1. Key Messages

A family history of acute cardiac events and sudden death should be elicited during the pre-anaesthetic check-up. The anaesthesiologist must identify the presence of a prolonged QTc interval pre-operatively on the ECG and an attempt should be made to avoid the drugs causing acquired QT interval. Patients with known Long QT Syndrome should be considered high risk for Torsades-de -Pointes throughout the entirety of the perioperative period and be closely monitored for worsening QTc prolongation and arrhythmias.

2. Introduction

Paroxetine is a selective serotonin reuptake inhibitor (SSRI). It is used to treat several diseases, including major depressive disorder, obsessive-compulsive disorder, social anxiety disorder, panic

Citation: Krishnaswami S and Masapu D. Paroxetine induced QT prolongation in a patient undergoing lumbar spinal fusion surgery. Case Rep Rev Open Access. 2026;7(1):153.

disorder, post-traumatic stress disorder, generalized anxiety disorder, and premenstrual dysphoric disorder. We present a case of arrhythmia in a patient taking paroxetine for depression undergoing lumbar spinal fusion surgery.

The patient continued to take paroxetine for depression and anxiety disorders till the day of surgery. During the conduct of the surgery, when the patient was under anaesthesia, the patient developed arrhythmia in the form of QTc prolongation on the ECG on the cardiac monitor. A literature review of such a condition presented no similarly documented cases in the past, and we present the identification and management of the same.

3. Case History

A 58-year-old female came with complaints of low back ache since one year. She was a known case of hypertension on tablet telmisartan 40 mg and hydrochlorthiazide 12.5 mg and depression on Paroxetine 25 mg. She had no history of coronary artery disease, thyroid disease or cerebrovascular disease. She was diagnosed with L4- L5 and L5-S1 listhesis and posted for L4- S1 fusion. Her pre-operative ECG had a regular rhythm and a rate of 89/min. Her echocardiographic assessment showed a concentric left ventricular hypertrophy, grade 1 left ventricular diastolic dysfunction, mild Tricuspid Regurgitation, Pulmonary Artery Hypertension, normal left ventricular systolic function with an ejection fraction of 60% and no regional wall motion abnormality. Anaesthesia was induced with injection fentanyl 100 mcg, inj. propofol 100 mg and inj. cisatracurium 10 mg. She was positioned on the prone position for surgery and anaesthesia was maintained with total intravenous anaesthesia with propofol target-controlled infusion according to the Schneider model and dexmedetomidine infusion at 0.5 mcg/kg/hr. The patient was ventilated with volume control mode of ventilation with air and oxygen. The patient was administered a Fraction of Inspired Oxygen (FiO₂) of 60%, fresh gas flow of 4 litres/min, a tidal volume of 440ml, PEEP of 5 cm H₂O and a respiratory rate of 14/min.

The patient developed arrhythmias soon after the infusion drugs were administered for maintenance of anaesthesia. QTc prolongation was observed on the cardiac monitor. It was identified by the increased distance between the QRS complex and the T wave, noted to be more than half of the previous RR interval (Fig. 1). It was initially isolated and found once every fifteen beats. The patient was immediately treated with Injection lidocaine 60 mg IV. The arrhythmia reduced for a period of one hour following which it recurred again. The second time that it occurred, the arrhythmia was persistent and was instantly identified by the changes seen on the intra-arterial waveform and the pulse oximetry waveform (Fig. 2). After eliminating all other causes for arrhythmia, including obtaining an arterial blood gas which showed all parameters within normal limits, a diagnosis of acquired QT prolongation was made with a probable cause being patient's intake of paroxetine. Injection magnesium sulphate 1 g in 100 ml Normal saline was then given intravenously over fifteen minutes, after which the arrhythmia resolved. Normothermia was maintained during surgery and there were no electrolyte imbalances pre-operatively or intra-operatively.

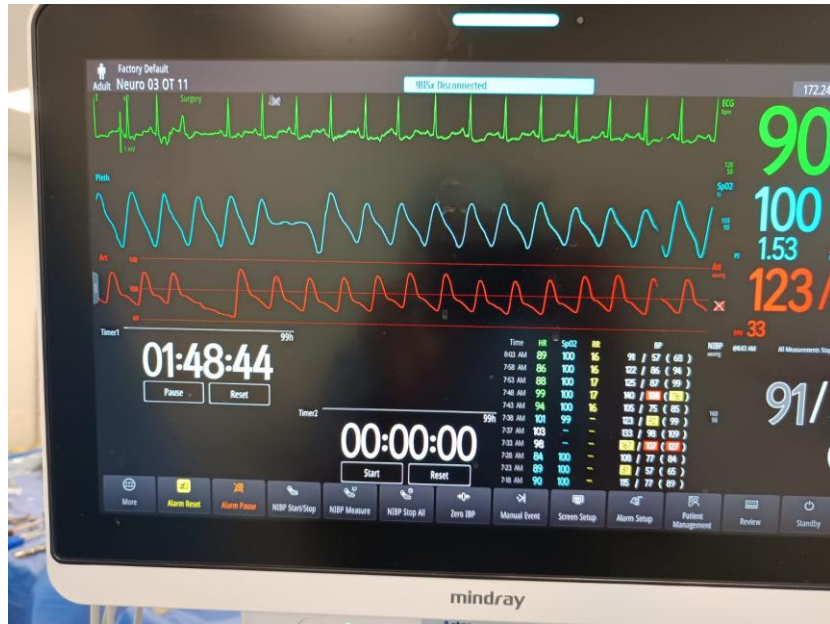

Fig.1. ECG tracing showing QTc prolongation, evidenced by an increased distance between the QRS complex and the T wave.

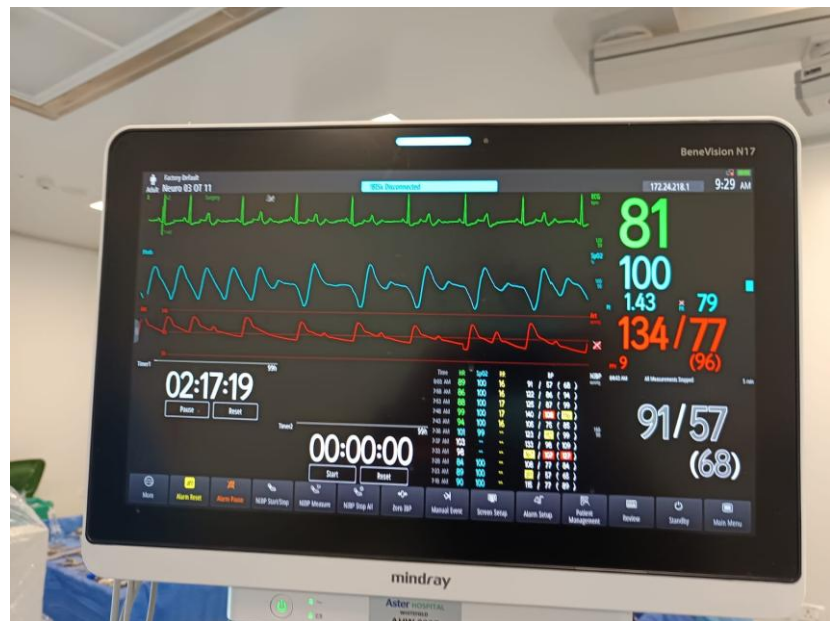


Fig. 2. Successive ECG beats demonstrating QTc prolongation, with corresponding effects on intra-arterial blood pressure and pulse oximetry waveforms.

4. Discussion

Paroxetine a selective serotonin reuptake inhibitor (SSRI), is a phenylpiperidine derivative. It is composed of a secondary amine present in the piperidine ring, which is in turn connected to

benzodioxol and fluorophenyl groups. Selective serotonin reuptake inhibitors (SSRI) are antidepressants that act by increasing the local concentration of the neurotransmitter at the synaptic junction and in the extracellular spaces through the blockade of the serotonin transporter (SERT) [1].

The primary target of paroxetine is the Serotonin Transporter (SERT), which is a type of monoamine transporter that transports serotonin from the synaptic cleft back to the presynaptic neuron [2]. The antidepressant paroxetine has been associated with Brugada syndrome and long QT syndrome. The cardiac voltage-gated sodium channel (Nav1.5) is related to both of these syndromes, which suggests that paroxetine may have an effect on this channel [3].

In vivo studies conducted by Plijter et al, 4 HEK-293 cells (cell line that was isolated from the kidney of a human embryo) expressing human Nav1.5 channels, paroxetine was found to inhibit peak Nav1.5 current density in a concentration-dependent manner; paroxetine was also found to inhibit Nav1.5 current by shifting its steady-state inactivation towards more hyperpolarizing potentials and increasing its rate of inactivation in a concentration-dependent manner [3]. Studies by Funk and Bostwick [4] showed that paroxetine indirectly caused QT prolongation in association with other drugs.

Acquired long QT syndromes are mainly caused by cardiac disease, electrolyte abnormalities or exposure to drugs that block rectifying potassium channels, especially rapid delayed rectifier (I_{Kr}) channels. The Management of Torsades de Pointes (TdP) or marked QT prolongation includes removal or correction of precipitants, including discontinuation of culprit drugs and institution of cardiac monitoring. Electrolyte abnormalities and hypoxia should be corrected, with potassium concentrations maintained in the high normal range. Immediate treatment of TdP is by intravenous administration of magnesium sulphate, terminating prolonged episodes using electrical cardioversion [5].

A family history of acute cardiac events and sudden death should be elicited during the pre-anaesthetic checkup. The anaesthesiologist must identify the presence of a long QT interval pre-operatively on the ECG and an attempt should be made to avoid the drugs causing acquired QT interval. Patients with known Long QT Syndrome should be considered high risk for TdP throughout the entirety of the perioperative period and be closely monitored for worsening QTc prolongation and arrhythmias. Total Intravenous anaesthesia is recommended for such patients and close monitoring for cardiovascular events should be made in the post-operative care unit.

5. Patient Consent

Written informed consent was obtained from the patient for publication of this case report and accompanying images. The patient was informed that complete anonymization cannot be guaranteed.

6. Conflict of Interest

The authors declare no competing interests.

7. References

1. Shrestha P, Fariba KA, Paroxetine AS. In: StatPearls [Internet]. Treasure Island (FL): StatPearls Publishing; 2023. [PubMed](#)
2. Davis BA, Nagarajan A, Forrest LR, et al. Mechanism of paroxetine (Paxil) inhibition of the serotonin transporter. *Sci Rep.* 2016;6:1–13. [PubMed](#) | [CrossRef](#)
3. Plijter IS, Verkerk AO, and Wilders R. The antidepressant paroxetine reduces the cardiac sodium current. *Int J Mol Sci.* 2023;18;24(3):1904. [PubMed](#) | [CrossRef](#)
4. Funk KA, and Bostwick JR. A comparison of the risk of QT prolongation among SSRIs. *Ann Pharmacother.* 2013;47(10):1330–1341. [PubMed](#) | [CrossRef](#)
5. Khatib R, Sabir FRN, Omari C, Pepper C, Tayebjee MH. Managing drug-induced QT prolongation in clinical practice. *Postgrad Med J.* 2021;97(1149):452-458. [PubMed](#) | [CrossRef](#)