CASE REPORTS AND REVIEWS: OPEN ACCESS

Case Report | Vol. 7 | Issue 2
ISSN (Online): 2583-892X

■ CASE REPORT

DOI: 10.70620/CRROA/v7i2/163

The Perfect Storm: Severe *Legionella* Pneumonia, Labile Anticoagulation, Refractory Atrial Fibrillation, Acute Kidney Injury, and Multifocal Ischemic Stroke in a Patient with Mechanical Heart Valves

Khiem Phan MD*, Samantha Watkins MD, Tahrier Sub Laban MD, Malak AL-Oqaily MD, Sarah Chang DO, Zainab Naqvi MD, Omar Nusir MD, Seth Coleman MD, Gregory Mock MD, and David E. Martin PhD

Unity Health White County Medical Center, Searcy, Arkansas, USA.

***Corresponding author:** Khiem Phan, MD, Unity Health White County Medical Center, Searcy, Arkansas, USA

Received: 27 September, 2026 · Accepted: 13 November, 2026 · Published: 27 November, 2026

© 2026 The Author(s). Published by Gnoscience Publishing House. This is an Open Access article distributed under the terms of the Creative Commons Attribution-NonCommercial-ShareAlike 4.0 International (CC BY-NC-SA 4.0) License.

ABSTRACT

Background: Legionnaires' disease can cause severe community-acquired pneumonia with multisystem complications, creating complex anticoagulation challenges in patients with mechanical heart valves.

Case Presentation: A 64-year-old man with heart failure with reduced ejection fraction (HFrEF; left ventricular ejection fraction [LVEF] 40–45%), permanent atrial fibrillation (AF) status post Maze procedure, mechanical mitral and tricuspid valves on chronic warfarin, diabetes, hypertension, obstructive sleep apnea (OSA), and tobacco use presented with dyspnea, hemoptysis, pleuritic chest pain, and fever. Imaging demonstrated right upper lobe pneumonia with pleural effusion, and respiratory testing detected *Legionella*. His course was complicated by progressive hypoxemic respiratory failure, refractory AF with rapid ventricular response (RVR), severe acute kidney injury (AKI), electrolyte abnormalities, and marked instability of the international normalized ratio (INR). His INR was 7.6 on admission with hemoptysis, increased to approximately 8.4 on hospital day 5, and was 8.0 on hospital day 7. While the INR remained supratherapeutic, he developed right-sided weakness on hospital day 7; serial imaging revealed evolving bilateral parietal and left frontal ischemic infarctions, progressing to profound right hemiplegia. He later developed hypercapnic respiratory failure requiring prolonged mechanical ventilation. After a 19-day hospitalization, he remained ventilator-dependent and was transferred to long-term acute care.

Conclusion: Severe infection can destabilize anticoagulation in mechanical-valve patients, creating competing hemorrhagic and thromboembolic risks that require frequent reassessment of anticoagulation, renal function, hemodynamics, and neurologic status.

Keywords: *Legionella*; Legionnaires' disease; Community-acquired pneumonia; Ischemic stroke; Mechanical heart valve; Atrial fibrillation; Acute kidney injury; Respiratory failure; Anticoagulation.

Citation: Phan K, Watkins S, Laban TS, et al. The Perfect Storm: Severe *Legionella* Pneumonia, Labile Anticoagulation, Refractory Atrial Fibrillation, Acute Kidney Injury, and Multifocal Ischemic Stroke in a Patient with Mechanical Heart Valves. Case Rep Rev Open Access. 2026;7(2):163. DOI: 10.70620/CRROA/v7i2/163

1. Introduction

Legionnaires' disease is a severe form of community-acquired pneumonia (CAP) caused predominantly by *Legionella pneumophila* [1]. Although *Legionella* accounts for only a proportion of CAP cases, its clinical importance is disproportionate because severe infection may cause progressive respiratory failure and substantial extrapulmonary organ dysfunction [1–3]. In addition to pulmonary infiltrates and hypoxemia, Legionnaires' disease may be accompanied by hyponatremia, acute kidney injury (AKI), rhabdomyolysis, gastrointestinal and hepatic abnormalities, encephalopathy, and cardiovascular complications [2–4]. Neurologic manifestations are well recognized, although encephalopathy and altered consciousness are more characteristic than persistent focal neurologic deficits or structural cerebral infarction [5].

Pneumonia itself is increasingly recognized as an acute cardiovascular stressor. In a systematic review of 92,188 patients with CAP, cardiovascular complications occurred in approximately 13.9% of hospitalized patients, including arrhythmias in 7.2%, heart failure in 9.2%, acute coronary syndromes in 4.5%, and stroke in 0.71% [6]. A subsequent meta-analysis found that CAP was associated with nearly threefold greater odds of stroke (OR, 2.88; 95% CI, 2.09–3.96) [7]. Proposed mechanisms linking acute infection with cardiovascular and thrombotic events include systemic inflammation, endothelial and platelet activation, coagulation abnormalities, sympathetic activation, hypoxemia, and destabilization of underlying cardiovascular disease [8].

These physiologic disturbances are particularly consequential in patients with mechanical prosthetic valves and atrial fibrillation (AF). Mechanical valves require long-term vitamin K antagonist therapy because inadequate anticoagulation increases the risk of prosthetic valve thrombosis and systemic embolization, whereas excessive anticoagulation increases hemorrhagic risk [9,10]. Warfarin has a narrow therapeutic window, and acute illness may destabilize anticoagulation through changes in nutritional intake, interacting medications, systemic inflammation, and evolving organ dysfunction [11].

We report a complex case of severe *Legionella* pneumonia complicated by progressive respiratory failure, refractory AF with rapid ventricular response (RVR), severe AKI, profound instability of the international normalized ratio (INR), and multifocal ischemic stroke. The case illustrates how these complications can interact and amplify one another, producing rapidly shifting hemorrhagic, thromboembolic, cardiovascular, renal, neurologic, and respiratory risks.

2. Case Presentation

A 64-year-old man with chronic heart failure with a left ventricular ejection fraction (LVEF) of 40–45%, permanent AF status post Maze procedure, mechanical mitral and tricuspid valve replacements on chronic warfarin therapy, obstructive sleep apnea, type 2 diabetes mellitus, hypertension, and tobacco use presented with 3–4 days of progressive dyspnea, hemoptysis, pleuritic chest pain, fever, night sweats, fatigue, and dizziness.

On admission, he was in AF with RVR and had acute hypoxemic respiratory failure requiring 2 L/min of supplemental oxygen. A chest X-ray on day 1 demonstrated right upper lobe ground-glass and air-space opacities with a small-to-moderate right pleural effusion. Respiratory molecular testing was positive for *Legionella*, whereas blood, sputum, and urine cultures remained negative. He was treated with intravenous (IV) azithromycin, 500 mg daily, and levofloxacin, 750 mg daily, for 7 days. After completing these, given the severity of his illness, he received empiric therapy with IV vancomycin and IV piperacillin–tazobactam (Zosyn) until the end of his hospital stay. By hospital day 8, his respiratory status had not improved. Chest computed tomography (CT) demonstrated nonspecific consolidation about the basal right lower lobe. Admission laboratory evaluation was notable for AKI, hyponatremia, hypomagnesemia, hyperglycemia, and markedly supratherapeutic anticoagulation with an INR of 7.6.

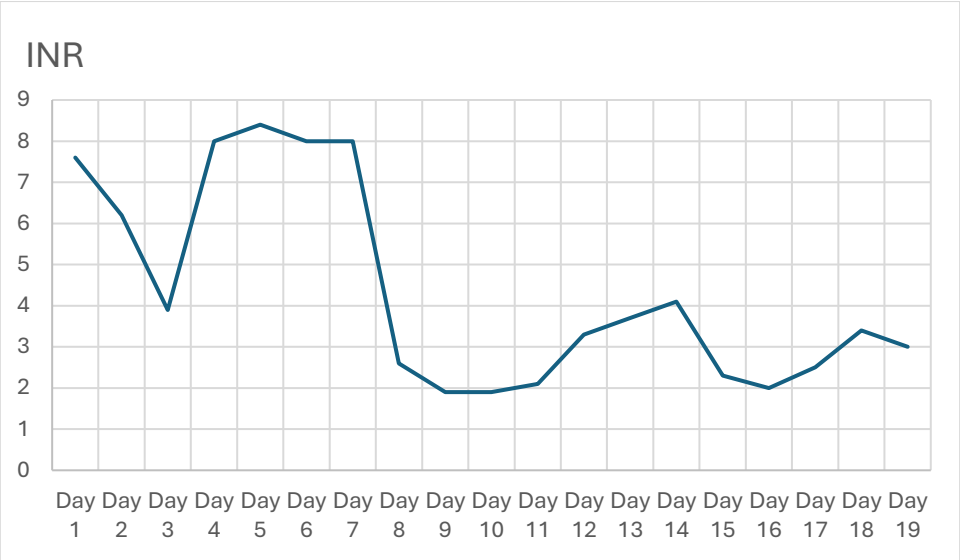

Graph 1. INR throughout the hospital course. The INR was markedly supratherapeutic on admission (7.6), increased to approximately 8.4 on hospital day 5, and was 8.0 on hospital day 7, coinciding with the onset of acute ischemic stroke.

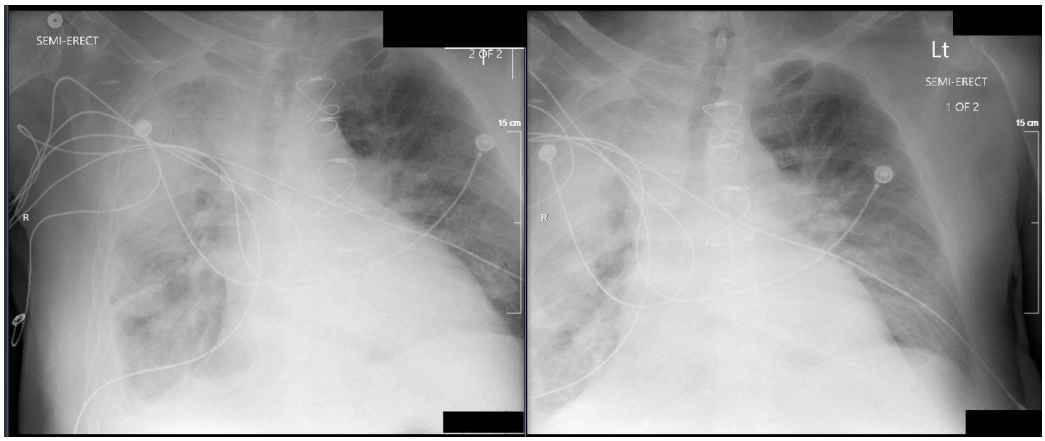

Fig. 1. Two chest radiographic views on day 1 showing vascular congestion, right pleural effusion, and airspace opacities.

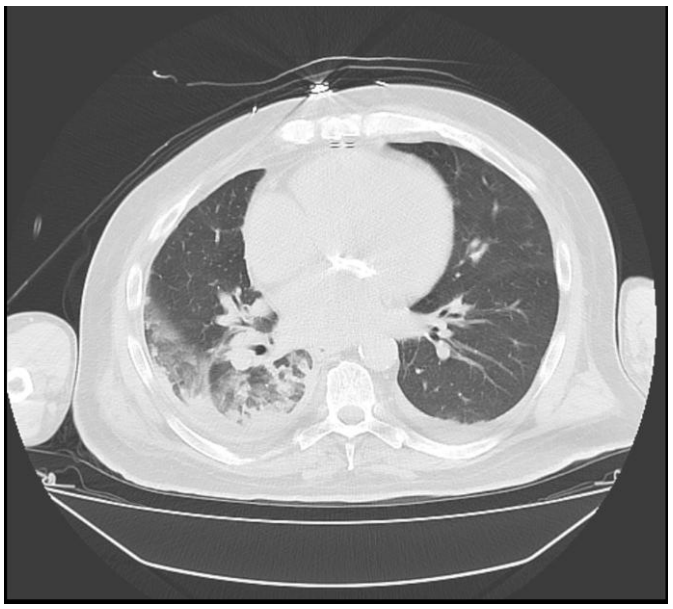

Fig. 2. Chest CT without contrast showing pleural effusions and nonspecific consolidation about the basal right lower lobe (day 8).

Despite antimicrobial therapy and supportive care, his pneumonia progressed, with escalating oxygen requirements necessitating bilevel positive airway pressure and high-flow oxygen. Concurrently, persistent AF with RVR proved difficult to control, with ventricular rates frequently ranging from 100 to 140 beats/min despite intravenous metoprolol, digoxin, and intermittent diltiazem infusions. Renal function also deteriorated substantially, with serum creatinine increasing from a baseline of approximately 1.0 mg/dL to a peak of 3.9 mg/dL.

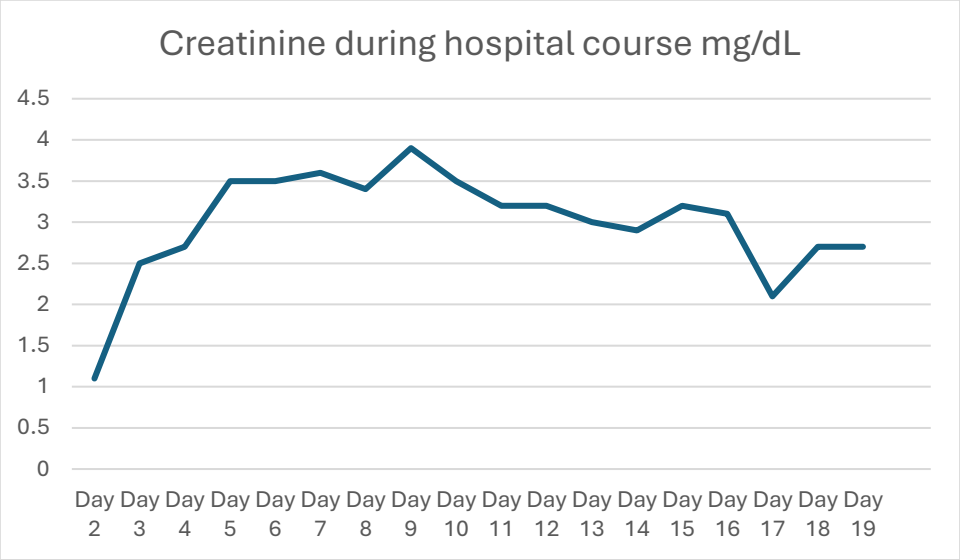

Graph 2. Creatinine during the hospital course (mg/dL).

Anticoagulation management became increasingly complex. On admission, the patient had severe supratherapeutic anticoagulation (INR 7.6) accompanied by hemoptysis and substantial bleeding risk. Warfarin was held from the first day of admission through the end of his hospital course, and he received vitamin K, 5 mg IV, once on the first day. Despite these interventions, his INR continued to increase, reaching approximately 8.4 on hospital day 5. He continued to receive vitamin K, 5 mg IV, once daily until day 7, after which his INR declined to 8.0 on day 7, which remained above the therapeutic range for mechanical prosthetic valves.

Approximately 7 days after admission, while his INR remained supratherapeutic at 8.0, he developed sudden right-sided weakness. Initial and repeat noncontrast head CT examinations showed no intracranial hemorrhage; however, subsequent neuroimaging, including magnetic resonance imaging (MRI) and repeat head CT, demonstrated evolving bilateral parietal and left frontal ischemic infarctions. His neurologic deficit progressed to profound right-sided hemiplegia with approximately 0/5 strength. Given his mechanical valves, AF, and absence of intracranial hemorrhage, intravenous unfractionated heparin was initiated on day 9 of his hospitalization after neurology consultation.

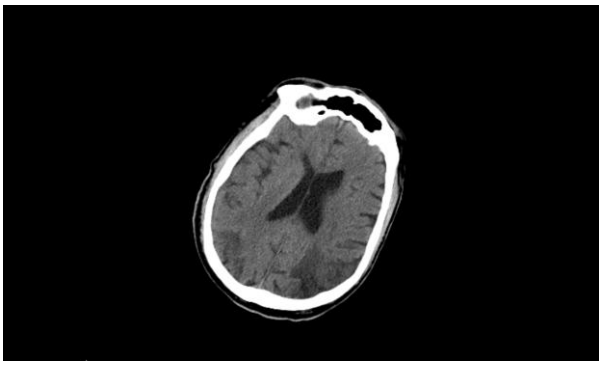

Fig. 3. Head CT without contrast showing evolving subacute infarcts in the bilateral parietal lobes.

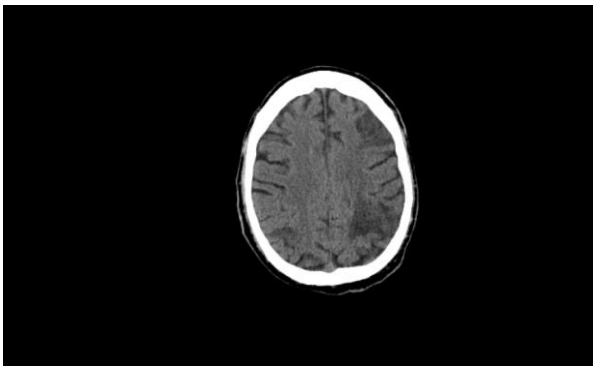

Fig. 4. Head CT without contrast showing evolving subacute infarcts in the bilateral parietal and left frontal lobes.

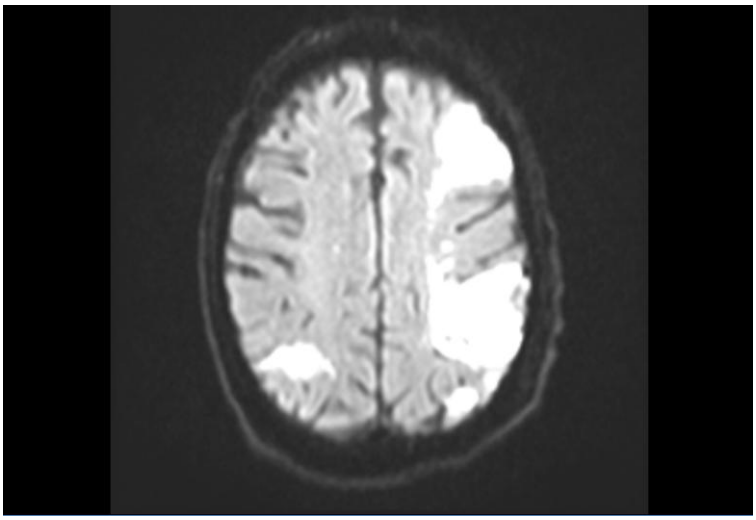

Fig. 5. MRI of the head/brain without contrast showing (1) acute infarcts in the left middle cerebral artery (MCA) distribution involving the left frontal and parietal lobes and (2) smaller acute infarcts in the right parietal lobe.

His condition subsequently deteriorated further, with worsening agitation, respiratory acidosis, acute hypercapnic respiratory failure, and impaired airway protection necessitating endotracheal intubation and mechanical ventilation. Attempts at ventilator liberation were unsuccessful because of persistent neurologic impairment and marked cardiovascular instability. During spontaneous breathing and extubation attempts, AF accelerated to ventricular rates of 160–180 beats/min, accompanied by episodes of severe hypertension with systolic blood pressure exceeding 230 mmHg, requiring multiple rate-control and antihypertensive therapies.

After approximately 9 days of mechanical ventilation and a 19-day hospitalization, he remained ventilator-dependent with substantial neurologic deficits. His course was ultimately characterized by severe *Legionella* pneumonia with progressive respiratory failure, refractory AF with RVR, severe AKI, markedly labile anticoagulation, and multifocal ischemic stroke. Following goals-of-care discussions, the family elected to continue life-prolonging treatment, and he was transferred to a long-term acute care facility for ventilator weaning, neurologic rehabilitation, anticoagulation management, and ongoing medical care.

3. Discussion

This case demonstrates how severe pneumonia can initiate a cascade of interacting pulmonary, cardiovascular, renal, hematologic, and neurologic complications in a patient with limited physiologic reserve. Rather than occurring independently, progressive respiratory failure, AF with RVR, AKI, warfarin instability, and multifocal ischemic stroke appeared to develop within an interconnected cycle in which each complication complicated management of the others.

First, severe Legionnaires' disease can produce substantial extrapulmonary organ dysfunction. In this patient, progressive pulmonary disease and increasing oxygen requirements occurred alongside worsening renal dysfunction, electrolyte abnormalities, and refractory tachyarrhythmia. Such multisystem deterioration is consistent with the recognized spectrum of severe Legionnaires' disease, which may involve renal, neurologic, cardiovascular, hepatic, gastrointestinal, and metabolic systems in addition to the lungs [2–5]. Accordingly, *Legionella* pneumonia likely served as an important physiologic stressor, producing inflammation, hypoxemia, metabolic stress, and sympathetic activation in a patient with substantial pre-existing cardiovascular vulnerability [8].

Second, pneumonia itself is increasingly recognized as an acute cardiovascular stressor. Approximately 13.9% of hospitalized patients with CAP experience cardiovascular complications, including arrhythmias, heart failure, acute coronary syndromes, and stroke [6]. Furthermore, CAP has been associated with increased odds of subsequent stroke [7]. New-onset AF is also well described during CAP, illustrating the arrhythmogenic effects of acute pulmonary infection [12]. Although our patient had permanent rather than new-onset AF, severe infection may have destabilized his pre-existing arrhythmia through inflammation,

hypoxemia, sympathetic activation, electrolyte disturbances, and changes in intravascular volume [8,13,14].

Once established, persistent tachyarrhythmia and AKI likely became additional physiologic stressors. Ventricular rates frequently remained between 100 and 140 beats/min despite multiple rate-control therapies, while serum creatinine increased from approximately 1.0 to 3.9 mg/dL. The resulting combination of hemodynamic stress, renal dysfunction, electrolyte disturbances, and medication limitations further complicated management.

A central feature of this case was the marked instability of anticoagulation. The patient initially presented with hemoptysis and an INR of 7.6, creating substantial hemorrhagic concern. Despite withholding warfarin and administering vitamin K, the INR increased to approximately 8.4 on hospital day 5 and was 8.0 on hospital day 7. The patient developed multifocal ischemic infarctions while the INR remained supratherapeutic. This case illustrates the complexity of balancing hemorrhagic and thromboembolic risks in a patient with mechanical prosthetic valves and permanent AF. INR variability and reduced time in the therapeutic range are associated with adverse thromboembolic and hemorrhagic outcomes among patients with mechanical heart valves [15]. Acute infection, altered nutritional intake, medication exposure, and evolving organ dysfunction likely contributed collectively to the unstable warfarin response [11,16]. Thus, the marked INR variability in this patient illustrates the central therapeutic dilemma of this hospitalization: the need to balance the risk of catastrophic bleeding against that of catastrophic thromboembolism, even while the INR remained above the therapeutic range.

The development of multifocal ischemic infarctions approximately 1 week after admission represented the point at which these risks converged. The bilateral parietal and left frontal distribution, together with permanent AF, mechanical prosthetic valves, and periods of inadequate anticoagulation, raised substantial concern for an embolic mechanism; however, definitive causality cannot be established from a single case.

Importantly, acute infection itself is recognized as a short-term trigger for ischemic stroke. In the Atherosclerosis Risk in Communities study, hospitalization for infection within the preceding 14 days was associated with a 7.7-fold higher odds of ischemic stroke (95% CI, 2.1–27.3), with the association decreasing as the interval between infection and stroke increased [17]. Similarly, the Cardiovascular Health Study found an approximately eightfold higher odds of ischemic stroke within 14 days of hospitalization for infection [18]. Proposed mechanisms include systemic inflammation, endothelial and platelet activation, tissue-factor-mediated coagulation, impaired fibrinolysis, and sympathetic activation [19,20].

Therefore, direct central nervous system invasion by *Legionella* was not necessary to explain the neurologic deterioration. Neuropathologic studies have shown that neurologic manifestations of Legionnaires' disease can occur without demonstrable direct cerebral infection [5,21]. In this patient, severe infection may instead have contributed indirectly by generating a systemic thrombo-inflammatory milieu superimposed on an exceptionally high-risk cardioembolic substrate. Nevertheless, the presence of mechanical valves, permanent AF, and unstable anticoagulation precludes attribution of the cerebral infarctions directly to *Legionella* infection.

The stroke, in turn, may have further amplified cardiovascular instability. Acute ischemic stroke can disrupt the central autonomic network and alter sympathetic-parasympathetic balance, producing abnormalities in heart rate, blood pressure, cardiac electrophysiology, and myocardial function [22,23]. This interaction is increasingly described within the framework of stroke-heart syndrome [24]. Although specific involvement of autonomic regulatory structures such as the insula was not documented in this patient and should not be assumed, his post-stroke episodes of AF with ventricular rates of 160–180 beats/min and systolic blood pressure exceeding 230 mmHg were compatible with severe autonomic and hemodynamic instability occurring in the setting of acute cerebral injury, pre-existing AF, and critical illness.

Finally, anticoagulation after ischemic stroke presented another competing-risk dilemma. Interruption of anticoagulation in a patient with mechanical valves may increase the risk of recurrent systemic embolism or prosthetic valve thrombosis, whereas aggressive anticoagulation may increase the risk of hemorrhagic transformation. In the multicenter ESTREM study of patients with mechanical heart valves and acute

ischemic stroke, full-dose heparin bridging was associated with a higher composite rate of ischemic and hemorrhagic outcomes than management without bridging, underscoring the narrow therapeutic margin in this population [25].

The principal clinical lesson is therefore not that *Legionella* directly caused the stroke, but that severe infection can rapidly destabilize multiple interdependent systems in patients with substantial baseline cardiovascular and thromboembolic risk. In such patients, the dominant clinical threat may shift rapidly between bleeding, thrombosis, arrhythmia, renal failure, respiratory failure, neurologic injury, and further cardiovascular and respiratory instability requiring frequent reassessment rather than reliance on a static management strategy.

4. Conclusion

Severe *Legionella* pneumonia in a patient with permanent AF and mechanical heart valves was followed by progressive respiratory failure, severe AKI, refractory tachyarrhythmia, marked INR instability, and multifocal ischemic stroke. The INR was supratherapeutic on admission, on hospital day 5, and around hospital day 7, when the ischemic stroke occurred, illustrating the difficulty of balancing hemorrhagic and thromboembolic risks in a patient with mechanical prosthetic valves and permanent AF during critical illness. Although the cerebral infarctions cannot be attributed directly to *Legionella*, severe infection may have amplified an already high-risk cardioembolic substrate through systemic inflammation and multisystem physiologic stress. This case underscores the importance of frequent reassessment of anticoagulation, renal function, hemodynamics, and neurologic status when severe infection destabilizes multiple interdependent organ systems.

5. Conflicts of Interest

The authors declare no conflicts of interest.

6. Funding

No external funding was received for this report.

7. Patient Consent

Written informed consent was obtained from the patient's legally authorized representative for publication of this case report and accompanying images.

8. References

1. Phin N, Parry-Ford F, Harrison T, et al. Epidemiology and clinical management of Legionnaires' disease. Lancet Infect Dis. 2014;14(10):1011–21. PubMed | CrossRef.

2. Mahgoub S, Awosika AO, Nguyen AD, et al. Legionnaires' disease. [Updated 2026 Apr 11]. In: StatPearls [Internet]. Treasure Island (FL): StatPearls Publishing; 2026 Jan-. Available from: https://www.ncbi.nlm.nih.gov/books/NBK430807/

3. Muder RR, Yu VL, Fang GD. Community-acquired Legionnaires' disease. Semin Respir Infect. 1989;4(1):32–9. PubMed

4. Rupasinghe S, Lemoh C. *Legionella* pneumonia complicated with severe acute kidney injury requiring continuous renal replacement therapy: a case series. J Med Case Rep. 2025;19(1):341. PubMed | CrossRef.

5. Johnson JD, Raff MJ, Van Arsdall JA. Neurologic manifestations of Legionnaires' disease. Medicine (Baltimore). 1984;63(5):303–10. PubMed | CrossRef.

6. Tralhão A, Póvoa P. Cardiovascular events after community-acquired pneumonia: a global perspective with systematic review and meta-analysis of observational studies. J Clin Med. 2020;9(2):414. PubMed | CrossRef.

7. Meregildo-Rodriguez ED, Asmat-Rubio MG, Rojas-Benites MJ, et al. Acute coronary syndrome, stroke, and mortality after community-acquired pneumonia: systematic review and meta-analysis. J Clin Med. 2023;12(7):2577. PubMed | CrossRef.

8. Corrales-Medina VF, Musher DM, Shachkina S, et al. Acute pneumonia and the cardiovascular system. Lancet. 2013;381(9865):496–505. PubMed | CrossRef.

9. Baber U, van der Zee S, Fuster V. Anticoagulation for mechanical heart valves in patients with and without atrial fibrillation. Curr Cardiol Rep. 2010;12(2):133–9. PubMed | CrossRef.

10. Edmunds LH Jr. Thrombotic and bleeding complications of prosthetic heart valves. Ann Thorac Surg. 1987;44(4):430–45. PubMed | CrossRef.

11. Hylek EM, Regan S, Go AS, et al. Clinical predictors of prolonged delay in return of the international normalized ratio to within the therapeutic range after excessive anticoagulation with warfarin. Ann Intern Med. 2001;135(6):393–400. PubMed | CrossRef.

12. Corica B, Tartaglia F, Oliva A, et al. Prevalence of new-onset atrial fibrillation in hospitalized patients with community-acquired pneumonia: a systematic review and meta-analysis. Intern Emerg Med. 2023;18(1):127–35. PubMed | CrossRef.

13. Scott L Jr, Li N, Dobrev D. Role of inflammatory signaling in atrial fibrillation. Int J Cardiol. 2019;287:195–200. PMC | CrossRef.

14. Chen PS, Chen LS, Fishbein MC, et al. Role of the autonomic nervous system in atrial fibrillation: pathophysiology and therapy. Circ Res. 2014;114(9):1500–15. PubMed | CrossRef.

15. Labaf A, Själander A, Stagmo M, et al. INR variability and outcomes in patients with mechanical heart valve prosthesis. Thromb Res. 2015;136(6):1211–5. PubMed | CrossRef.

16. Clark NP, Delate T, Riggs CS, et al. Warfarin interactions with antibiotics in the ambulatory care setting. JAMA Intern Med. 2014;174(3):409–16. PubMed | CrossRef.

17. Cowan LT, Alonso A, Pankow JS, et al. Hospitalized infection as a trigger for acute ischemic stroke: the Atherosclerosis Risk in Communities Study. Stroke. 2016;47(6):1612–7. PubMed | CrossRef.

18. Elkind MS, Carty CL, O'Meara ES, et al. Hospitalization for infection and risk of acute ischemic stroke: the Cardiovascular Health Study. Stroke. 2011;42(7):1851–6. PubMed | CrossRef.

19. Oh SE, Parikh NS. Recent advances in the impact of infection and inflammation on stroke risk and outcomes. Curr Neurol Neurosci Rep. 2022;22(3):161–70. PubMed | CrossRef.

20. Violi F, Cangemi R, Calvieri C. Pneumonia, thrombosis and vascular disease. J Thromb Haemost. 2014;12(9):1391–400. PubMed | CrossRef.

21. Pendlebury WW, Perl DP, Winn WC Jr, et al. Neuropathologic evaluation of 40 confirmed cases of *Legionella* pneumonia. Neurology. 1983;33(10):1340–4. PubMed | CrossRef.

22. Barkhudaryan A, Doehner W, Jauert N. Autonomic dysfunction after stroke: an overview of recent clinical evidence and perspectives on therapeutic management. Clin Auton Res. 2025;35(4):553–63. PubMed | CrossRef.

23. Winder K, Villegas Millar C, Siedler G, et al. Acute right insular ischaemic lesions and poststroke left ventricular dysfunction. Stroke Vasc Neurol. 2023;8(4):301–6. PubMed | CrossRef.

24. Scheitz JF, Sposato LA, Schulz-Menger J, et al. Stroke-heart syndrome: recent advances and challenges. J Am Heart Assoc. 2022;11(17):e026528. PubMed | CrossRef.

25. Paciaroni M, Caso V, Romoli M, et al. Anticoagulation in acute ischemic stroke patients with mechanical heart valves: to bridge or not with heparin. The ESTREM study. Eur Stroke J. 2023;8(4):1030–40. PubMed | CrossRef.